PINNING SUPRACONDYLAR HUMERUS FRACTURE IN CHILDREN
TIPS AND TRICKS

Dr. Ashish Ranade

MS, MRCS, Pediatric Orthopaedic and Scoliosis fellowships(USA)

ashishranade@yahoo.com

POSITIONING

- Supine
- Hand table
- C arm from foot end
- Prep and drape whole extremity
- If necessary C should rotate for good lateral view

REDUCTION

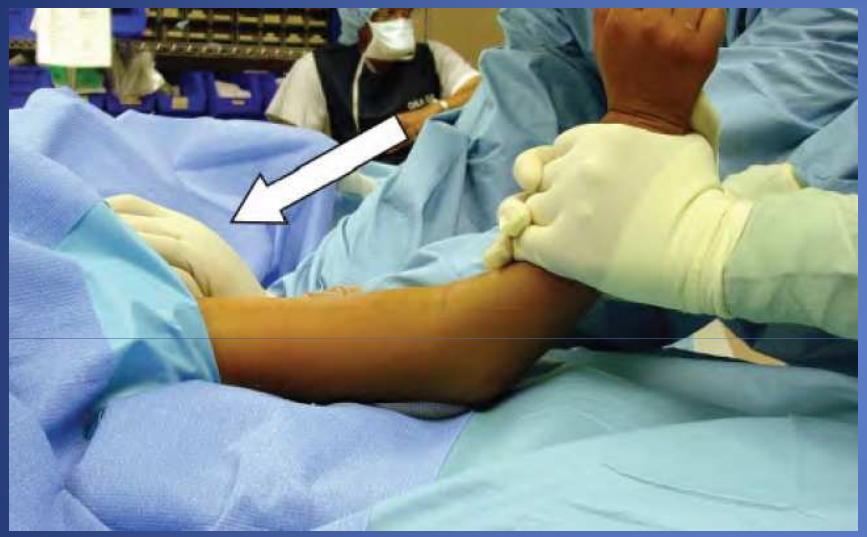

- Traction in 30 degrees of flexion
- Stay away from anterior aspect of elbow
- Correct varus/valgus deformity

REDUCTION- 'RULE OF THUMB'

Thumb should point towards the direction of displacement

Posterolaterally displaced fractures- Supinate the forearm

REDUCTION

Posteromedially displaced fractures- pronate the forearm

REDUCTION

- Flexion by pressure over olecrenon
- Fingers should touch shoulder- if not-fracture is in extension
- Check radial pulse

CHECK FOR ADEQUACY OF REDUCTION

Medial & Lateral Columns

Anterior Humeral Line

CHECKLIST

- Anterior humeral line should pass through centre of capitellum
  - Beware in kids <4 years :AHL may normally pass through anterior 1/3rd of capitellum (Herman, JBJS 2009)
- Restoration of rotation
- Comminution of Medial column/Lateral column
- Some lateral translation is acceptable
- Radial pulse

FIXATION WITH K WIRES

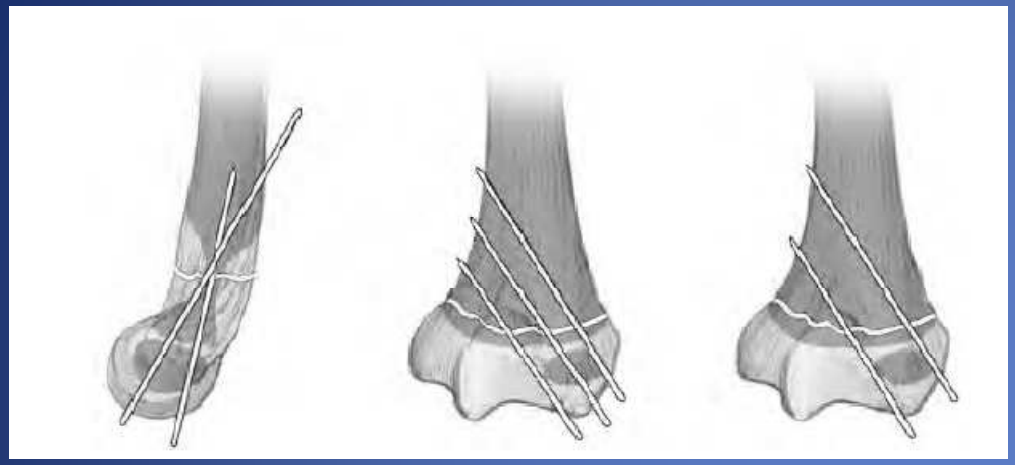

- 1.6 or 1.8 mm K wires 2 or 3 from lateral side
- Maintain elbow in hyperflexion
- Start with lateral pin
- Add medial pin if necessary

LATERAL ENTRY WIRES/CROSS PINNING?

- No appreciable clinical difference in two techniques
- Biomechanically cross pinning is more stable
- Cross pinning is biomechanically stable

(Lee, JPO 2012, Zhao CORR 2013)

IDEAL CONFIGURATION

- Pins engaging medial and lateral columns
- Divergent or parallel
- Acceptable to cross olecrenon fossa (4 cortices – more stability)

IDEAL CONFIGURATION

STRESS TEST

- After k wire placement apply varus, valgus stress to elbow and check it under continuous flouroscopy
  - Watch for opening at fracture site
- Stress test in lateral view
  - Gentle flexion extension
- May need to revise wires if fixation is unstable

WHEN TO USE 3 LATERAL WIRES?

OFF

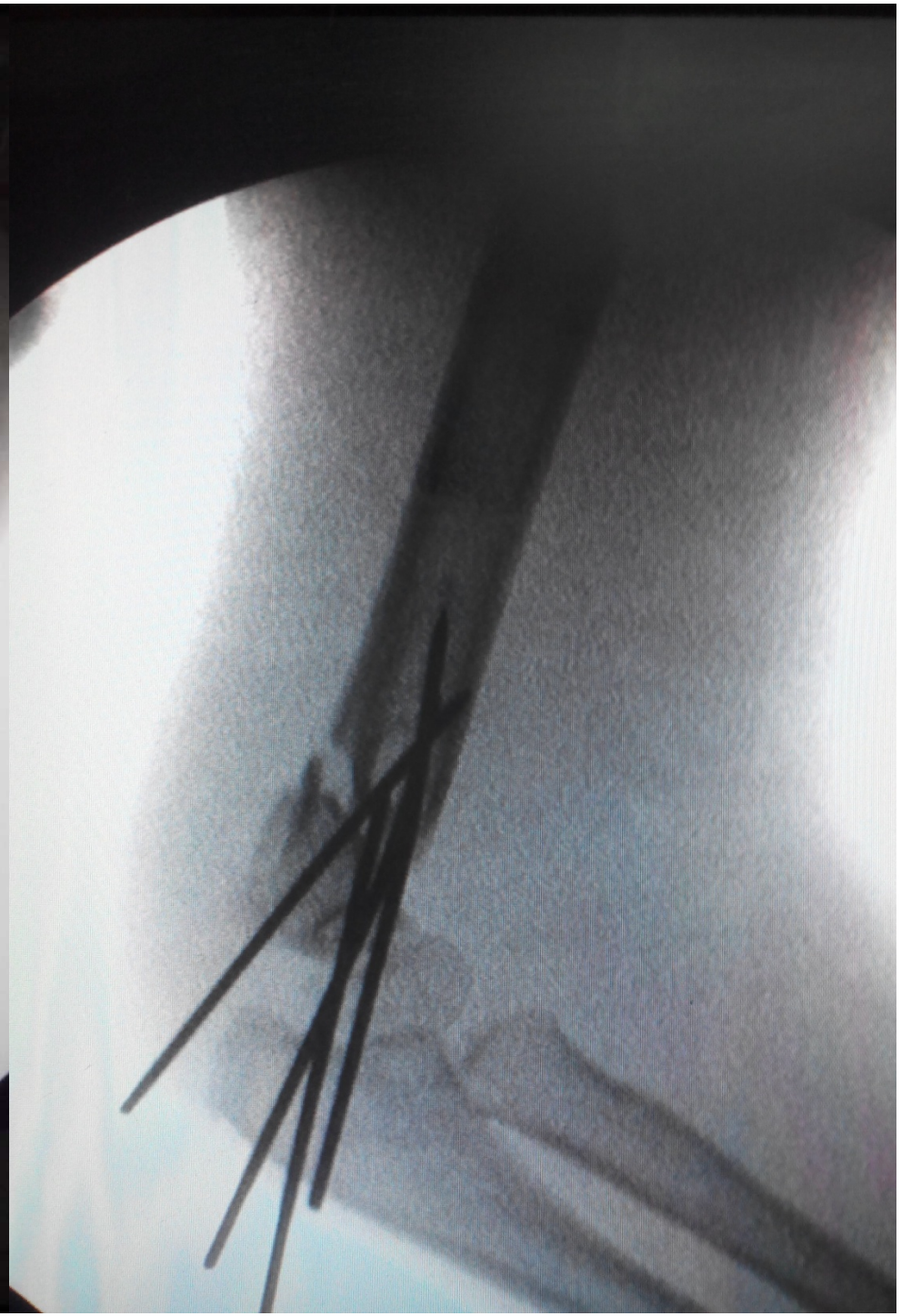

HOW TO MINIMIZE ULNAR NERVE INJURY?

- Keep elbow in extension: Ulnar nerve subluxes anteriorly with hyperflexion
- Start anteriorly on medial epicondyle
- Mini-open: make an incision over medial epicondyle and use drill guide to protect soft tissues getting caught in the wire

PITFALLS TO AVOID

- Convergent k wires
- Wires not having hold in medial column

POST OPERATIVE PROTOCOL

- AE cast/slab in 70 degrees flexion- avoid hyperflexion (high risk of compartment syndrome)
- K wire removal after 3-4 weeks

THANK YOU

ashishranade@yahoo.com